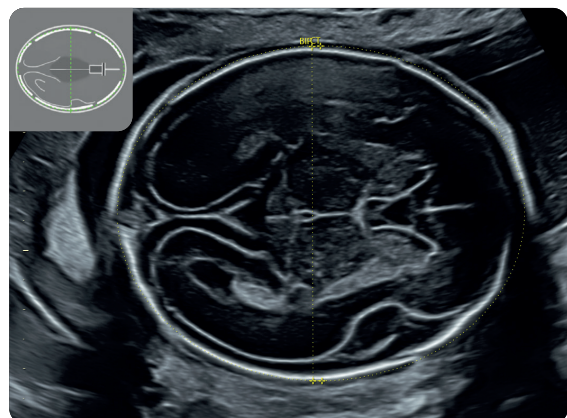
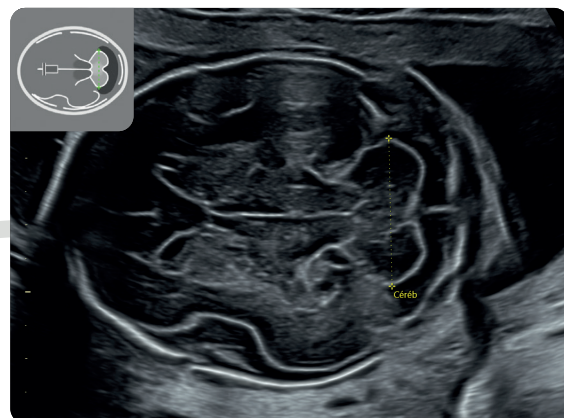


Recommandations CNEOF (2023)

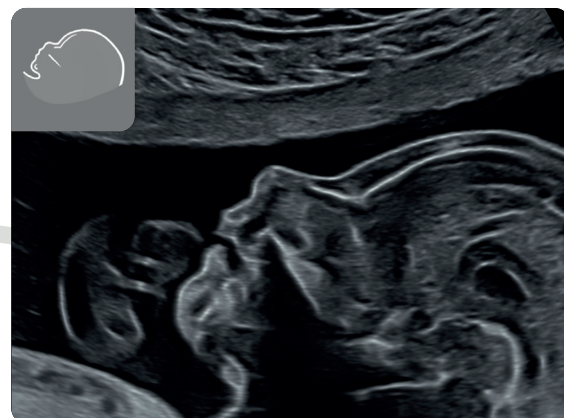
2^E TRIMESTRE



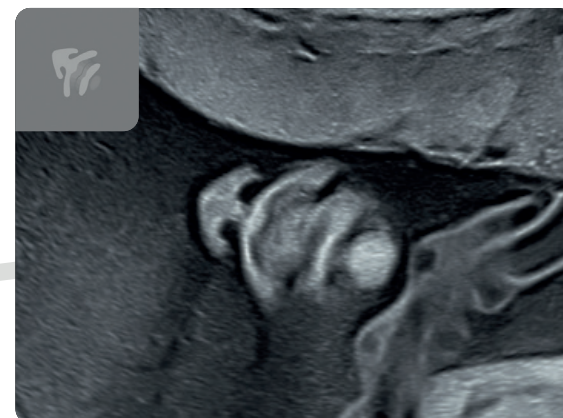
BIP et PC



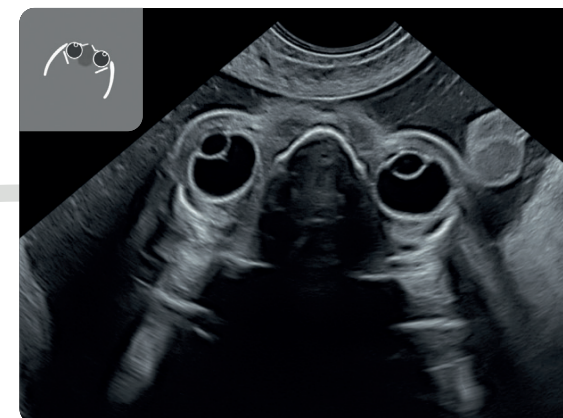Cervelet



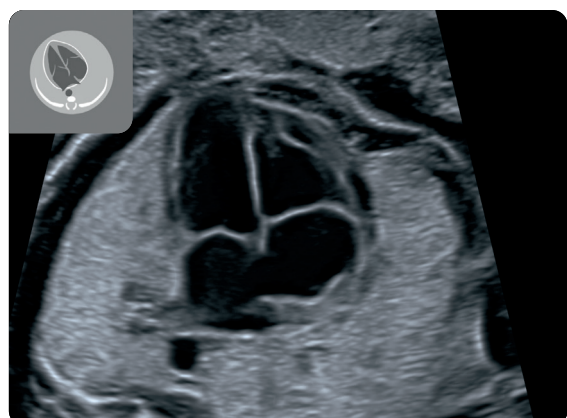
Profil



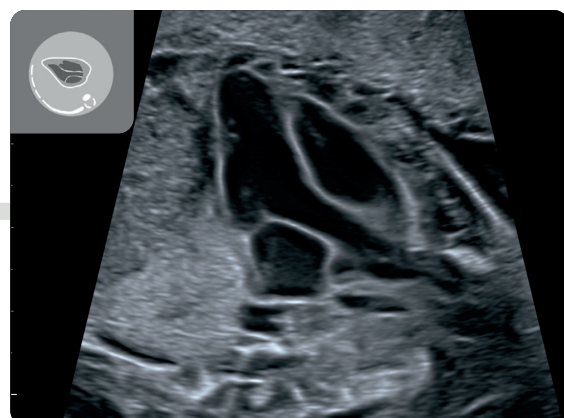
Coupe Nez-Bouche



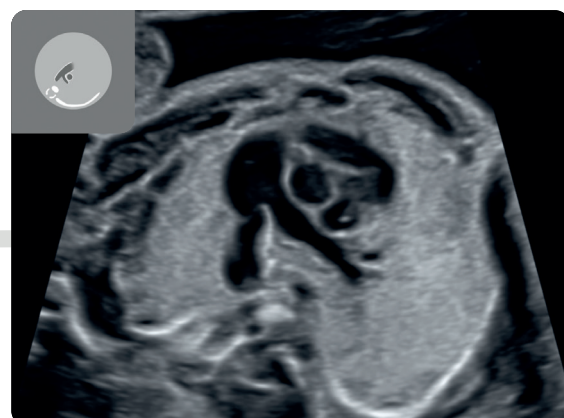
DIO



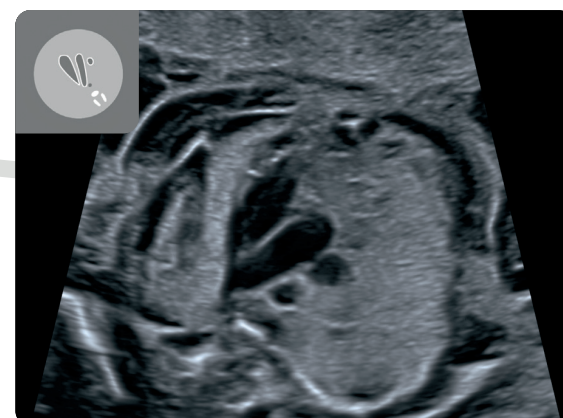
4 Cavités cardiaques



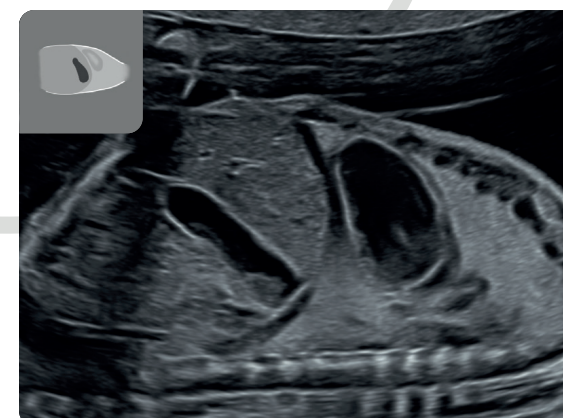
Voie d'éjection gauche avec AO



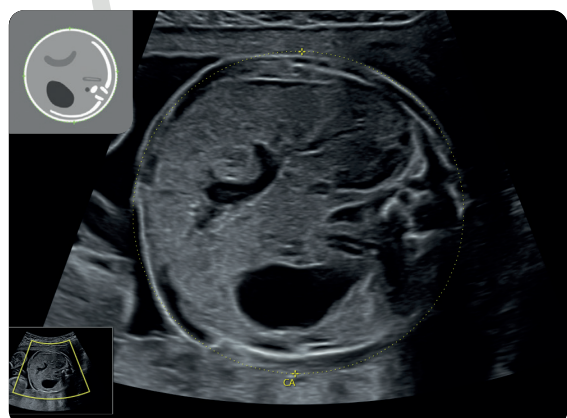
Bifurcation de l'AP en AP Drote et CA (Canal Artériel)



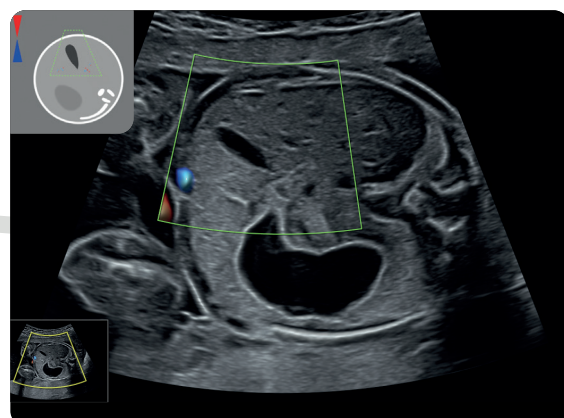
Coupe des 3 vaisseaux



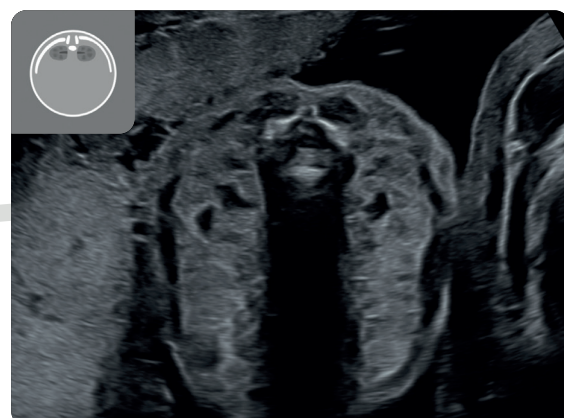
Coupe thoraco-abdominale para-sagittale gauche



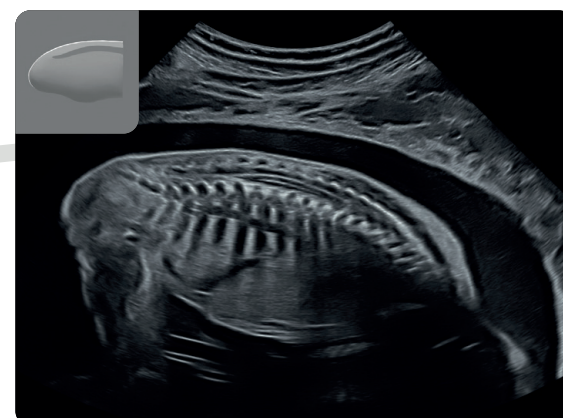
PA



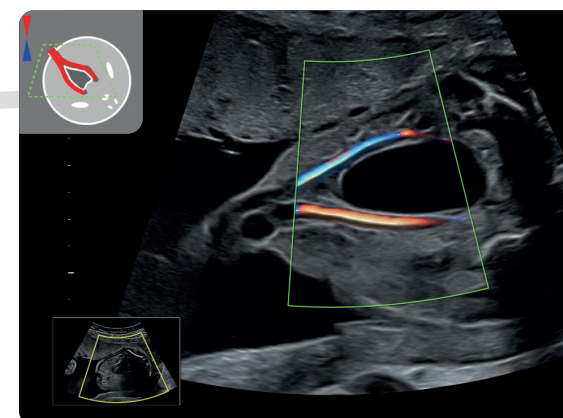
Vésicule Biliaire



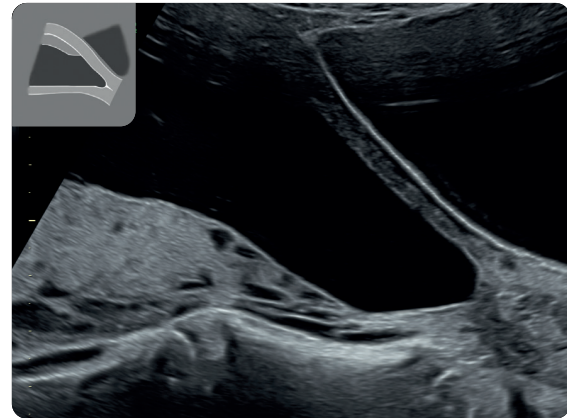
Reins et rachis en coupe axiale



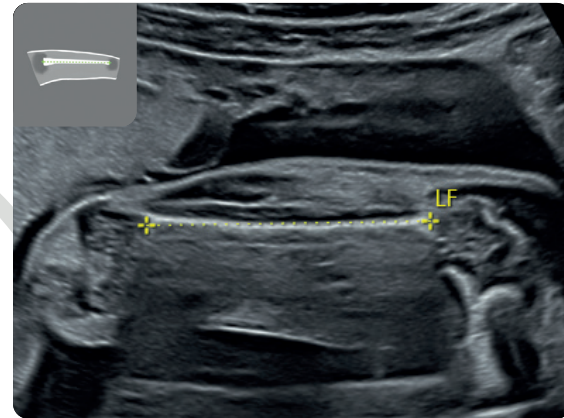
Rachis en coupe sagittaire



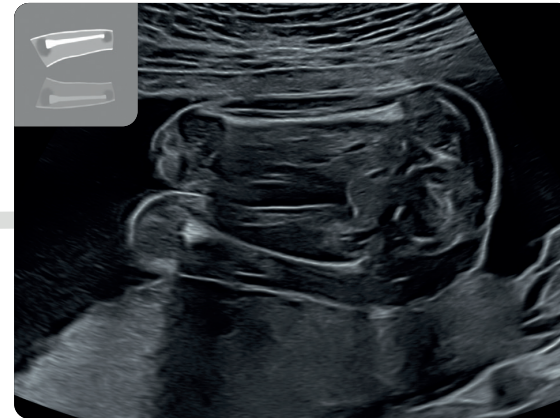
Vessie et paroi abdominale



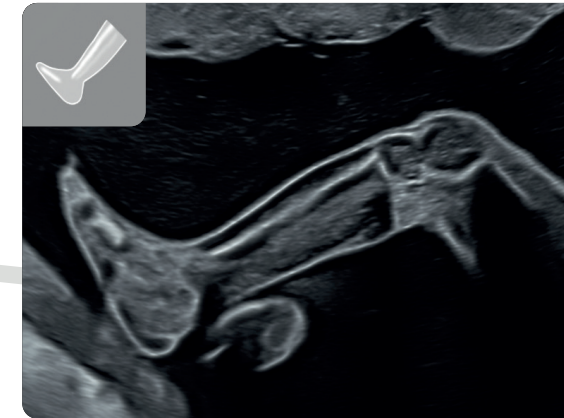
Placenta et col



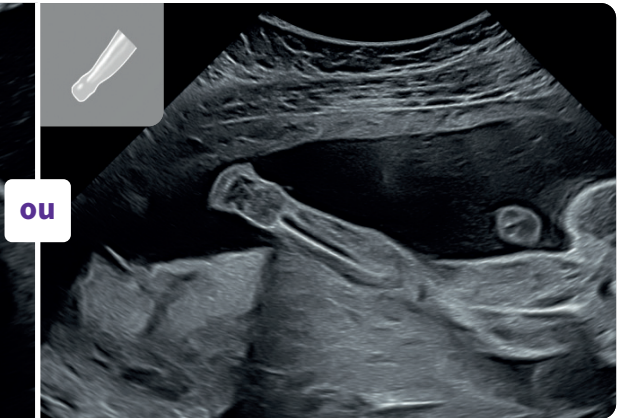
LF



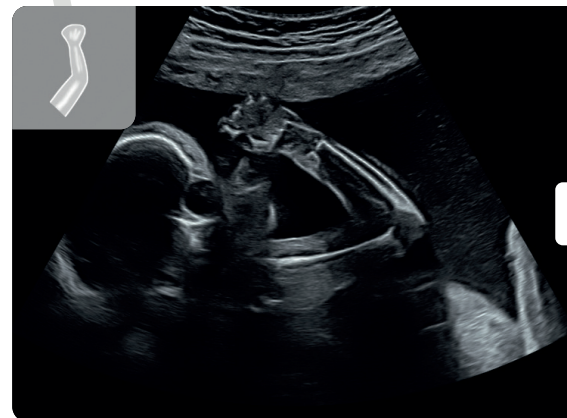
2 membres inférieurs



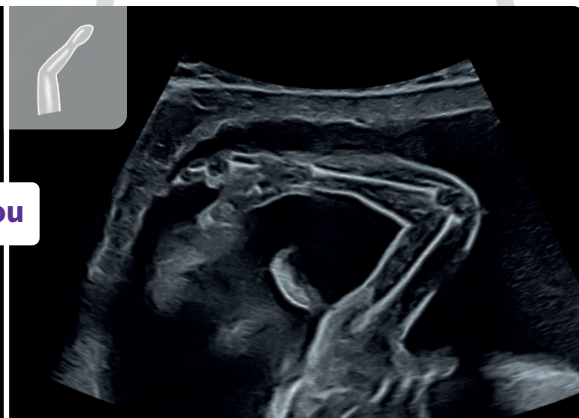ou



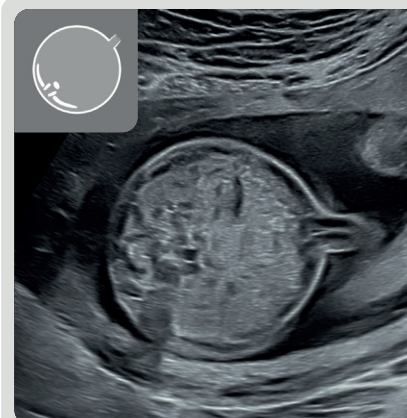
1 image des 3 segments
pour chaque membre inférieur



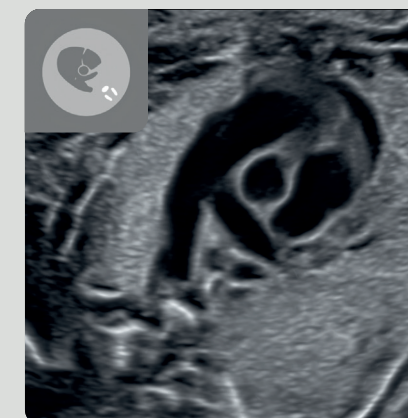
ou



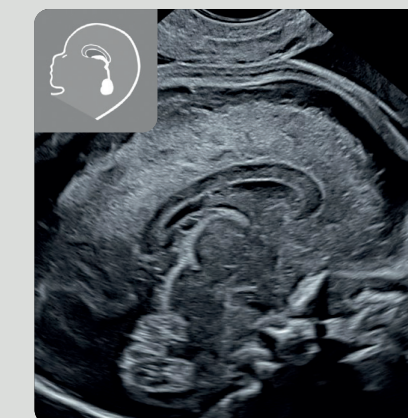
1 image des 3 segments
pour chaque membre supérieur



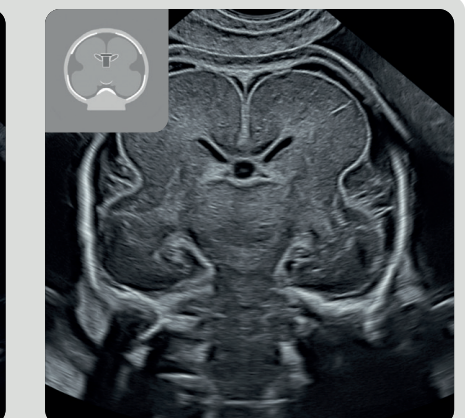Paroi abdominale



Enroulement de l'AP
autour de l'Ao



Coupe sagittale
médiane
du pôle céphalique



Coupe coronale
médiane
du pôle céphalique

Iconographie complémentaire